

Dental Care Information for Owners



*The
Donkey
Sanctuary*



Lee Gosden BAEDT & Gemma Lilly BSc (Hons) EDS, BAEDT

Co-sponsored by The
DONKEY BREED SOCIETY

The Donkey Sanctuary Dental Care Information for Owners

Dental disease is second only to hoof problems as the most common medical condition of the donkey.

This leaflet is a guide to aid owners and carers to recognise and prevent dental health problems.

Donkeys may have anywhere between 16 and 44 teeth depending on age, gender, and the presence of small non functional wolf teeth.

Donkeys evolved to roam around 15km/day in very arid climates across rugged terrain, in search of sparse and coarse grasses as well as other fibrous plant materials. In order to cope with long duration feeding of highly abrasive feed matter; donkeys have developed long crowned teeth that are designed to wear constantly. Donkeys have a finite amount of tooth available, and as the chewing surface wears, the long crown held in reserve erupts towards the point at which the upper and lower teeth meet.

During adolescence, the donkey will shed the temporary 'milk' teeth, to allow for the permanent teeth to take their place. This shedding takes place at regular intervals, starting with the central incisors from around the age of 2.5 years. The mouth is not dentally complete until around 5 years of age. It is important that the milk teeth or 'caps' are shed at the correct time; if they are retained they are likely to cause infection, pain and trauma. If they shed too soon, the underlying permanent tooth may not have had sufficient time to develop fully; even if the tooth looks normal, it will be at much greater risk of increased wear and cavities.

Dental Care as part of Donkey Management

All donkeys should have their teeth regularly checked by an appropriate professional. It is important that they are checked soon after birth to identify any serious problems. From then on it is recommended that all donkeys are checked twice annually, as their teeth shed, erupt and wear at a rapid rate whilst young. Your vet or EDT (Equine Dental Technician) will advise you of appropriate appointments specific to your donkey. For geriatric donkeys, it is probable that dental check ups will be needed more frequently.

It is the owner's responsibility to employ an appropriate person to complete dental assessments and procedures, and with the current explosion of practitioners, this is no easy task. It is highly recommended that you consult either an Equine Dental Technician or Veterinarian who has gained the BEVA/BAEDT qualifications.

Do not wait until your donkey loses weight, has difficulty or stops eating, or develops malodorous breath; dental problems are likely to be severe in these cases.

Prevention is Key to Maintaining Good Oral Health

There is also no need to wait until your donkey's teeth are razor sharp, or you notice any of the typical warning signs before booking an appointment with your Vet/EDT. Dental treatments are much more effective when carried out at regular intervals.

Signs of Dental Problems

- **Difficulty chewing**

- Quidding occurs as a result of not being able to chew food thoroughly enough for swallowing.
- Balls ('quids') of feed (usually hay/straw) are dropped from the mouth.
- Owner may witness head tilting, tooth grinding, spilling feed from mouth, extended feeding times.

- **Difficulty nipping grass with incisors**

- May relate to loose, diseased, or absent incisor teeth.

- **Strong smelling mouth**

- Sign of painful periodontal (gum) disease.
- Usually food matter that has collected in and around teeth.
- Food begins to rot, irritating local tissues.
- Infection occurs, which deepens with continued food entrapment.
- Commonly this cycle persists until the affected tooth/teeth are lost.
- May indicate tooth root abscess.

- **Nasal discharge**

- Milky white to bright yellow/green and or smell indicates possible infection.
- May be respiratory associated.
- If swellings of the face accompany nasal discharge, it may be a sign of a tooth root infection; cases of sinusitis may be dentally related.
- In all cases, do not delay in seeking veterinary attention.

- **Excessive salivation**

- May indicate foreign body.
- May indicate ulcerations, lacerations, periodontal disease, fractures, or possibly difficulty swallowing.

- **Behavioural changes**

- May alter behaviour in many ways.
- Irritability, aggression, withdrawn.
- May display stereotypical behaviours; crib biting, wind sucking.
- Do not ignore long term quirks of behaviour; if dentistry has been neglected, these could be possible signs.

- **Food packing**

- Considered an attempt to alleviate painful contact with cheek tissues, i.e. sharp teeth.
- May be due to sharp and or displaced teeth.

- **Whole grains or long stem fibre in faeces**

- Suggesting that food has not been ground down sufficiently.

- **Colic episodes**

- Colic in donkeys is significantly associated with dental disease.

- **Inability or no desire to eat**
- Serious consequences in the donkey; Hyperlipaemia.
- Seek veterinary attention immediately.
- **Weight loss**
- Weight loss in donkeys has been linked to dental disease.
- **Bitting/ridden/driven problems**

REMEMBER; THERE MAY BE NO SIGNS AT ALL!

Donkeys are famed for stoicism, but could it be that we just do not notice the signs? Donkeys that appear very healthy or even obese may have significant dental problems.

Typical problems

- **Sharp points**
- **Malocclusions** (*A malocclusion refers to an abnormality regarding the contact made between opposing teeth. Occlusion simply means the contact between opposing teeth*).
- **Wave**
- **Steps**
- **Shear**
- **Displacements**
- **Periodontal disease**
- **Loose or missing teeth**
- **Incisors** – *may appear to be in good alignment and in healthy condition, however; they are not necessarily a picture of the whole mouth. Remember, the teeth reach as far back as the level of the eye and can only be properly observed by a qualified professional using a full mouth speculum (gag).*

Prevention and management

Nearly all dental anomalies can be **prevented** by thorough, regular assessment and treatment. It is very important that you have your donkeys' teeth checked particularly if they have other health issues; impaired immunity can accelerate oral disease.

As donkeys become older, there is less enamel content in their teeth, this reduces the grinding capabilities. Older donkeys that may or may not have received dental care may start to lose or wear out their teeth and are more likely to lose weight. Supplementary feeding then becomes a necessity. *For feeding advice, please consult the following leaflets:*

- *What to feed your donkey*
- *Feeding the elderly donkey*
- *Hyperlipaemia fact sheet*
- *Care of the geriatric donkey*
- *Body condition score chart*

Useful links

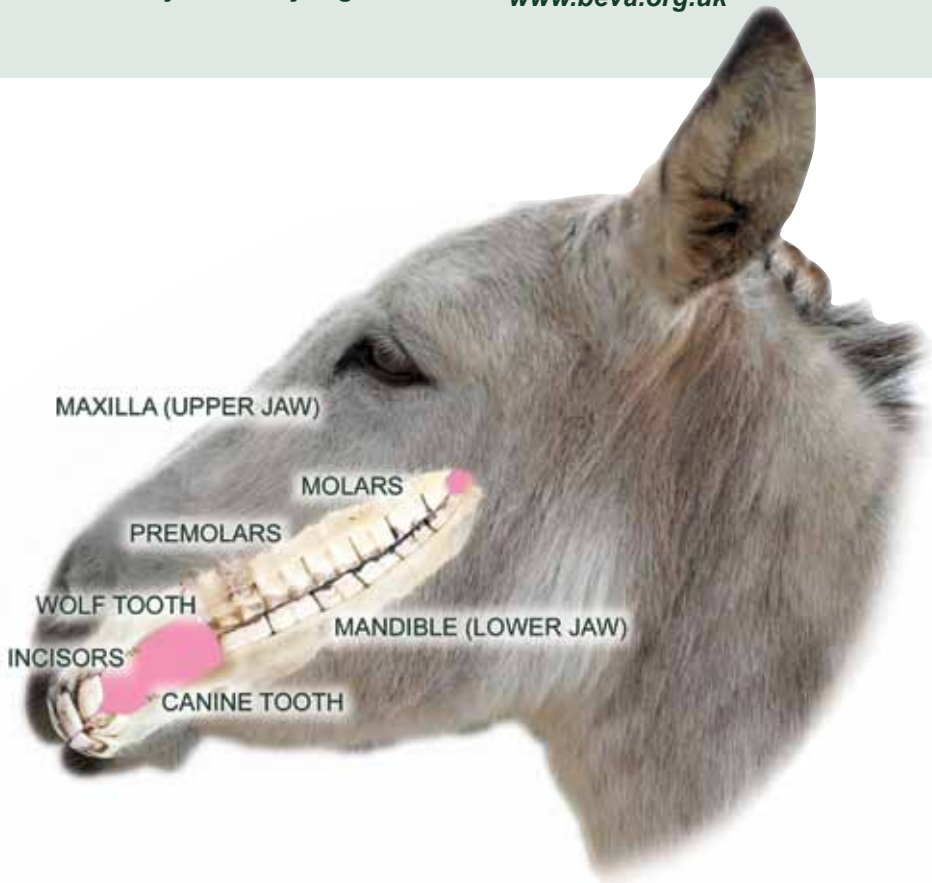
The Donkey Sanctuary
Sidmouth
Devon
EX10 0NU
01395 578222

www.thedonkeysanctuary.org.uk

The Donkey Breed Society
www.donkeybreedsociety.co.uk

British Association of Equine Dental
Technicians
www.baedt.com

British Equine Veterinary Association
www.beva.org.uk

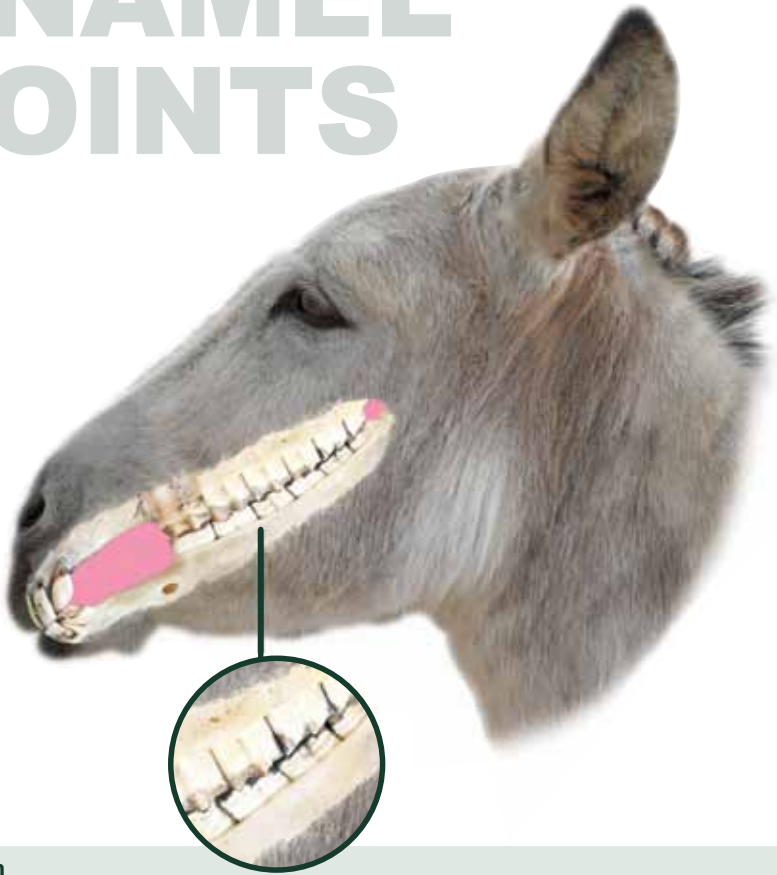


Dental conditions of the donkey

Donkeys are extremely popular in the UK; there are approximately 4,800 donkeys and mules at the Sanctuary in UK and Ireland, 1,400 of which are in foster homes. Given the stoical nature of the donkey, it is common to find severe dental abnormalities in patients that are eating, and are of normal/above normal weight or even obese. Often, by the time the donkey displays difficulty eating and or weight loss, the problems may be too severe to correct. It is therefore important that dental examinations and treatment become routine procedure for all donkeys from an early age.

This section is intended to present common dental abnormalities found in the donkey, the causes and consequential effects in addition to possible solutions.

ENAMEL POINTS



Definition

Sharp points that naturally form on the inside of the lower teeth and the outside of the upper teeth.

Cause

Occurring over time as a consequence of the donkey not chewing as far sideways (commonly as a result of using large quantities of processed feedstuffs), resulting in the unopposed edges becoming longer with the enamel forming razor sharp points.

Consequences

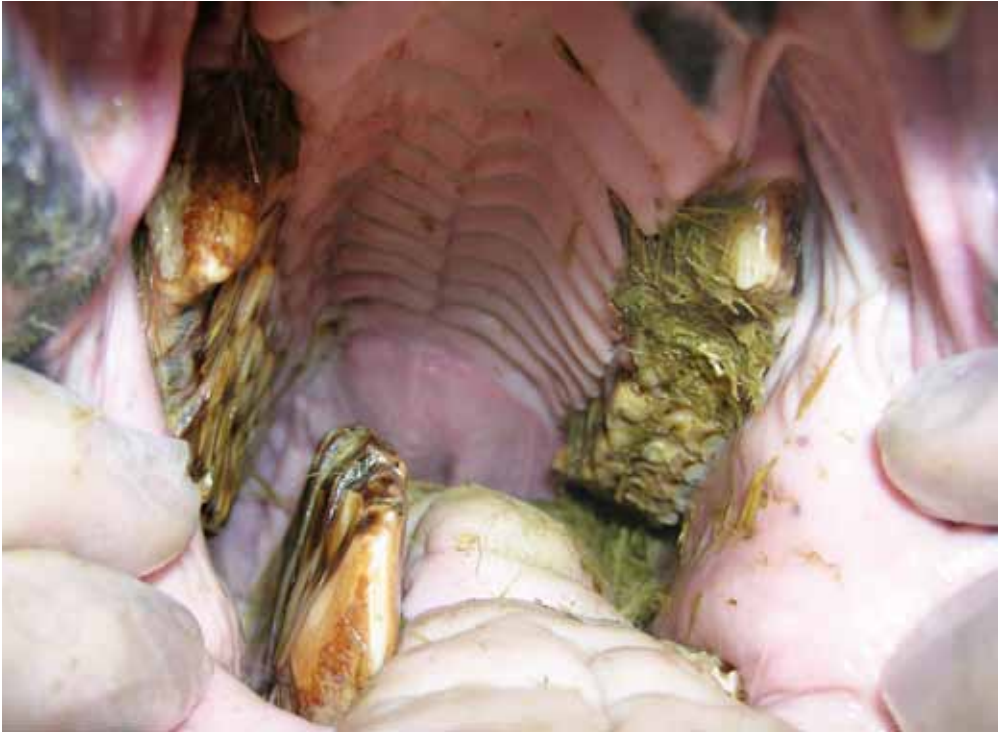Enamel points may cause trauma to adjacent soft tissues (tongue, cheeks), causing pain/discomfort when eating, and also during bridled work when the noseband pulls the cheeks tightly against the enamel points.

This is a prime example of a self-perpetuating disorder, as the enamel points further restrict sideways movement of the jaws, causing longer and longer points to form, and possibly an alteration in the chewing surface angle.

Solution

Routine, regular reduction of the points.

SHEAR MOUTH



Definition

Increase in chewing surface angle from the normal of around 15° , to on occasions beyond 45° .

Cause

Lack of full sideways movement of the jaw results in the teeth becoming longer and sharper on the inside of the lower teeth and the outside of the upper teeth; eventually this increases the table angle.

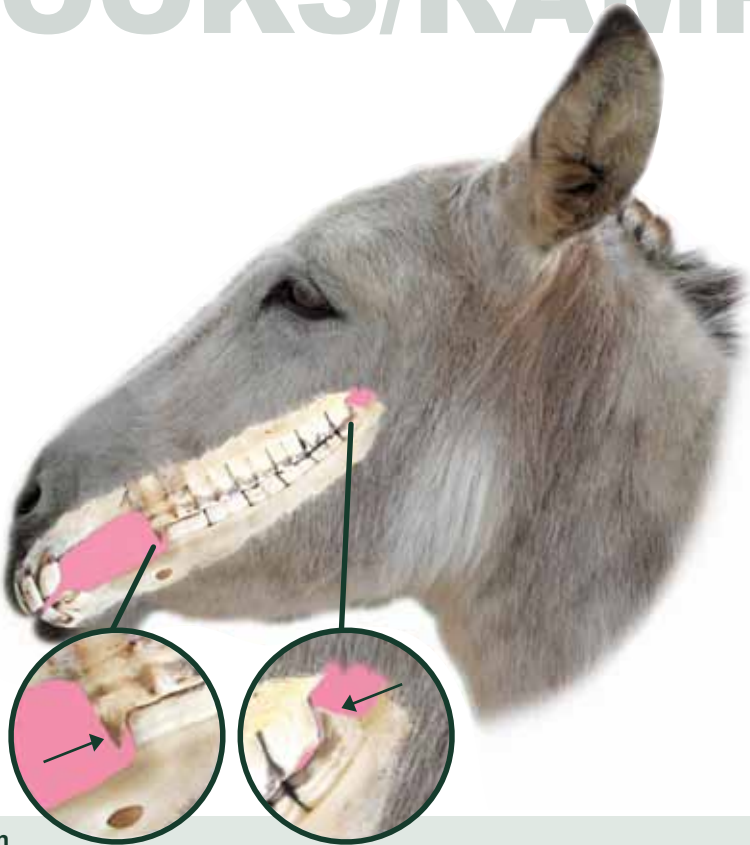
Consequences

Further restriction of the sideways movement of the jaw. Usually poor feed utilisation owing to difficulties chewing and retaining feed in the mouth.

Solution

Correction over time to restore the correct table angle. May require several treatments, and depending on severity, may not be rectifiable.

HOOKS/RAMPS



Definition

A partial overgrowth of a cheek tooth, so as to appear as a hook on upper teeth or a ramp on lower teeth.

Caudal; pertains to the back of the mouth **Rostral;** pertains to the front of the mouth

A rostral hook is therefore a partial overgrowth of the upper front cheek tooth. Most types of overgrowth tend to affect opposite pairs of teeth, so usually both upper/lower front/back cheek teeth will be affected.

Cause

Congenital conditions arising from a disparity in length of the upper and or lower jaw. Also occurs from permanent feeding at elevated heights, or from a malocclusion which results in the unopposed portion freely erupting into the available space.

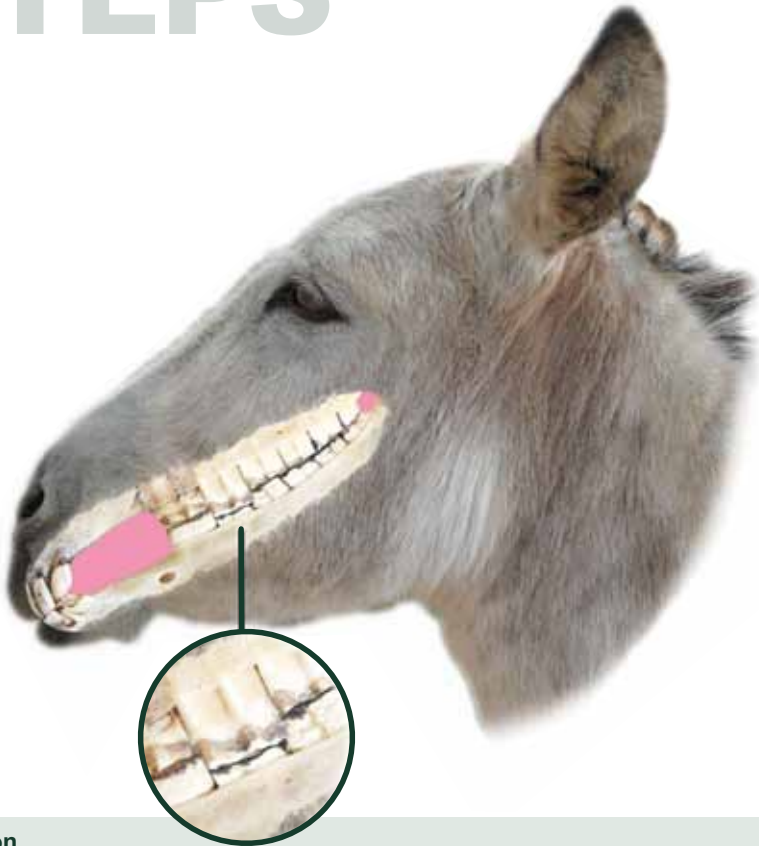Consequences

Poor jaw mobility, excessive wear of opposing teeth, trauma and resultant infection to adjacent/opposing structures (potentially life threatening).

Solution

Regular attention will avert formation. Reduction of the dominant portion of tooth. Requires regular maintenance, depending on severity may require sedation for power treatment(s).

STEPS



Definition

An overgrowth of step appearance. Usually refers to an overgrowth of one whole tooth.

Cause

Occurs as a result of a missing tooth, extreme uneven wear, or delayed/asymmetrical shedding of milk teeth.

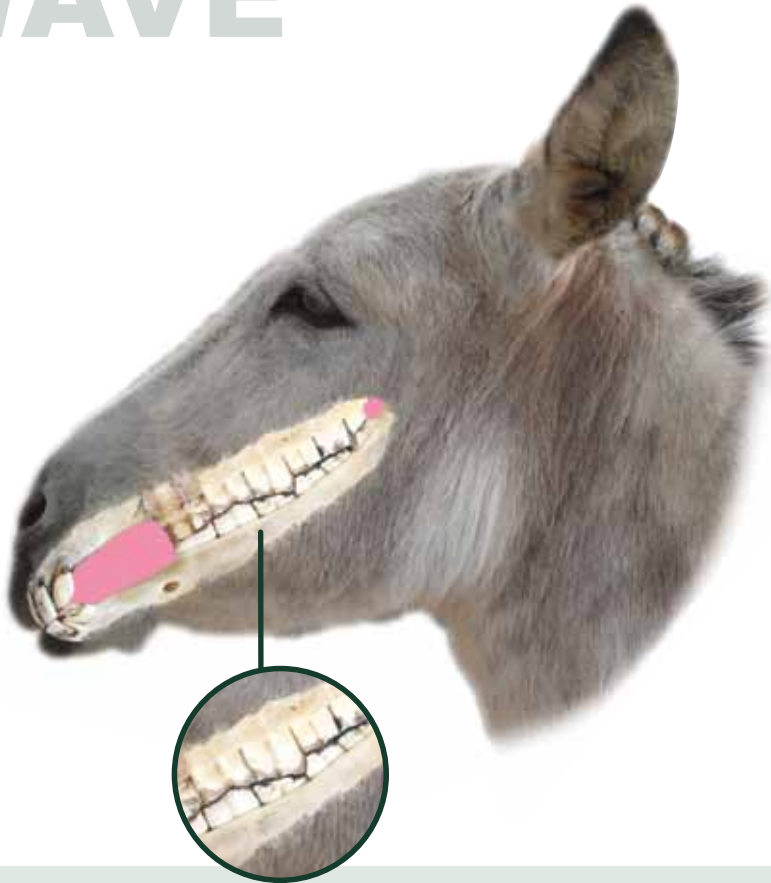
Consequences

Poor jaw mobility, excessive wear if opposing tooth exists, uneven wear of remaining dentition. Retained milk teeth that eventually become infected, or overgrown teeth that penetrate into the upper jaw at the level of the sinuses will cause secondary sinusitis. Chronic food infiltration of the maxillary (upper jaw) bony structures is catastrophic, and usually leads to euthanasia. Overgrowths usually cause varying degrees of gum disease.

Solution

Reduction of the overgrown tooth. Could be averted through regular attention. Very regular maintenance required dependant on severity.

WAVE



Definition

The cheek teeth arcades develop a wave like appearance; this is a series of overgrowths affecting many teeth.

Cause

Retained milk teeth, missing teeth, extra teeth, displaced teeth, hooks, ramps and steps may all be precursors to wave mouth, as well as excessive wear and gum disease.

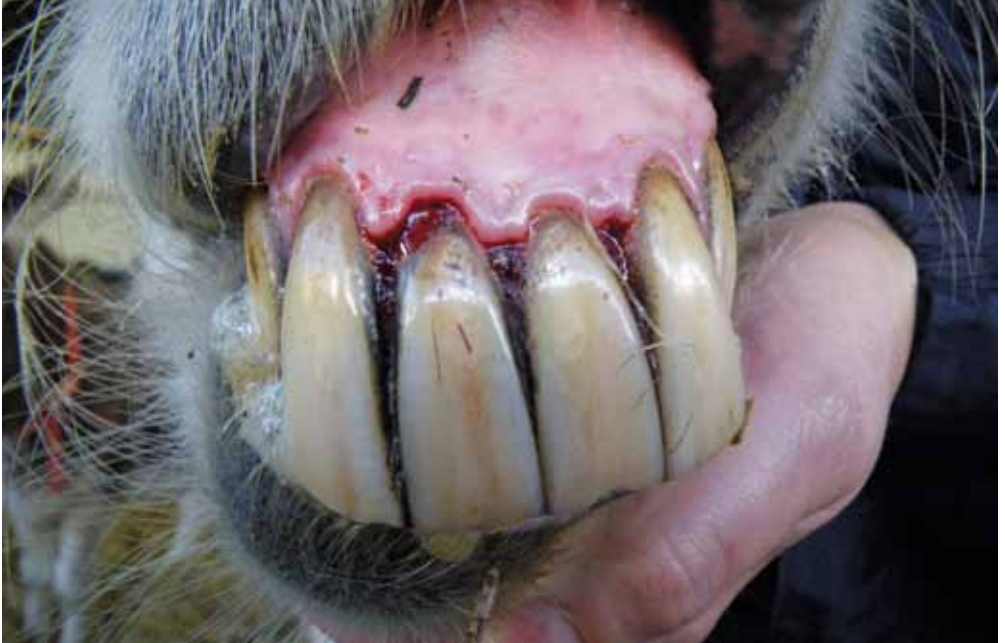Consequences

Progressive condition may cause premature tooth loss, poor jaw mobility, difficulty eating, ridden/driven problems.

Solution

Regular attention will avert. Reduction of the overgrown teeth to restore normal function, this may take many treatments and may require sedation. In advanced cases restoration is not possible.

GUM DISEASE



Definition

Disease (usually bacterial) of the gingiva (termed periodontal disease; disease surrounding the tooth).

Cause

Overgrowths, displacements and sharp jagged edges all cause feed retention around the affected teeth/tooth. Feed material and saliva make ideal conditions for bacteria to proliferate. Food and bacteria irritate and penetrate the gum, causing it to detach from the tooth; the infiltration becomes deeper.

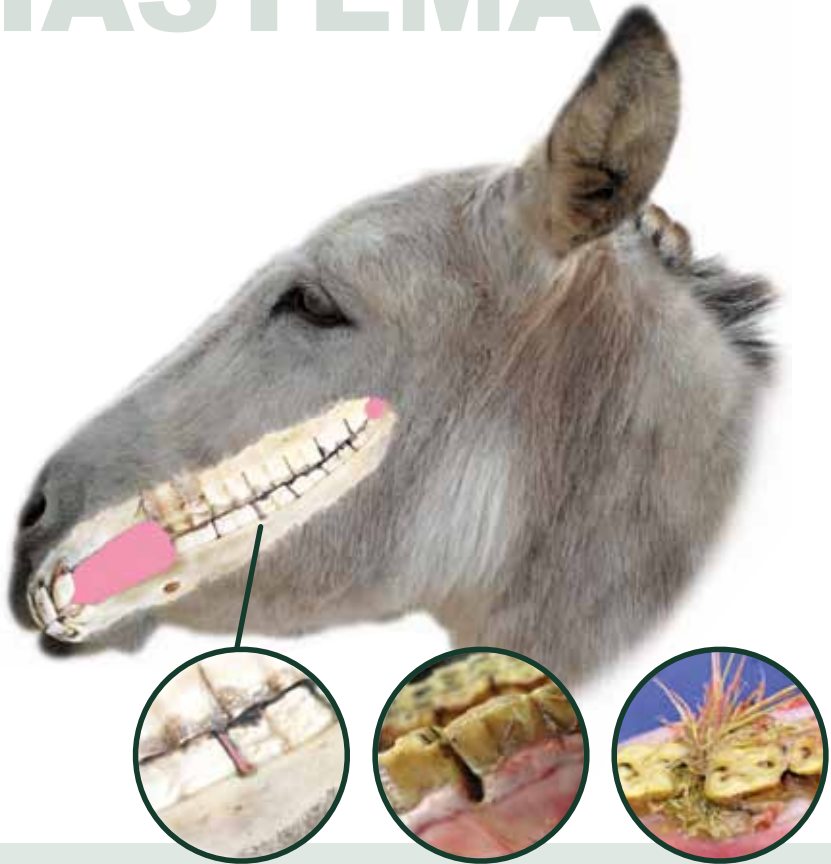Consequences

Chronic periodontal disease can cause significant pain upon eating and tooth loss. It can also accelerate displacements, and can even cause osteomyelitis, a condition where the underlying bone becomes infected. Deep pockets caused by food and bacterial infiltration can also cause tooth root infections/abscesses. There is also a growing body of evidence linking gum disease with systemic illnesses such as heart disease. Spaces between teeth (diastema) are strongly associated with periodontal disease and carry a prevalence rate of 72% in donkeys over 20 years. Periodontal disease has a prevalence of 30% in donkeys over the age of 20 years and is a major cause of tooth loss.

Solution

Early, regular attention will avert. It is usually not possible to reverse gum disease when it is passed superficial stages. Correction of malocclusions early on is key to preventing gum disease.

DIASTEMA



Definition

Diastema means a pathological (disease causing) space between adjoining teeth.

Cause

Often results as the forces of chewing lever overgrown teeth apart. A partially overgrown tooth may erupt into and separate two adjoining teeth. May also occur naturally due to age (tooth roots taper inwards), or as a result of chronic gum disease.

Consequences

Food infiltration and bacterial proliferation, as per gum disease. Diastemata are strongly associated with impaction colic and weight loss/poor body condition score.

Solution

Regular attention may avert. Reduce overgrowths and sharp edges to improve the flow of food. Usually not possible to cure in the older animal, or where gum disease is more than superficial. In cases where a diastema is continually trapping food that the animal is not able to clear, it is possible to perform a bridging procedure using modern dental impression materials.